

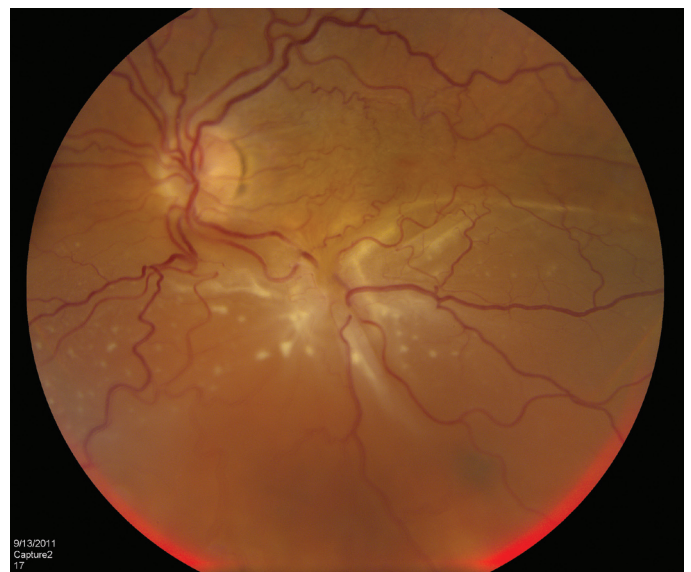## Complex Retinal Detachment:

**Proliferative Vitreoretinopathy and Giant Retinal Tears** Proliferative vitreoretinopathy (PVR) is a condition in which retinal scar tissue, or “membranes” form; this may occur with a retinal detachment. A key risk factor for developing PVR is a giant retinal tear—a large tear that involves at least 25% of the retina. When PVR or a giant retinal tear is present, a retinal detachment is classified as “complex.”

**Causes:** Complex retinal detachments due to PVR are associated with retinal scar tissue or membranes; these ultimately contract, pull, and stretch the retina, causing retinal tears or stretch holes. When the detached retina contracts, so-called “star folds” often develop (*Figure 1*).

The reason these membranes form is uncertain, but it is thought to be due to cells growing on the retinal surface. Passage of liquefied vitreous gel through a retinal tear or hole results in an accumulation of fluid under the retina (*subretinal fluid*) and progression of the retinal detachment.

PVR most commonly occurs after a previous (primary) retinal detachment repair surgery. PVR is the most common cause of primary retinal detachment surgery failure, occurring in approximately 5% to 10% of all retinal detachments. Retinal detachment with a giant retinal tear, however, is relatively uncommon.



**Figure 1.**

A patient with complex retinal detachment due to PVR in the left eye. A retinal “star fold” is present in the inferior macular with associated subretinal fluid. (Photo courtesy Carl Regillo, MD)

*continued next page*

## Complex Retinal Detachment: Proliferative Vitreoretinopathy and Giant Retinal Tears *continued from previous page*

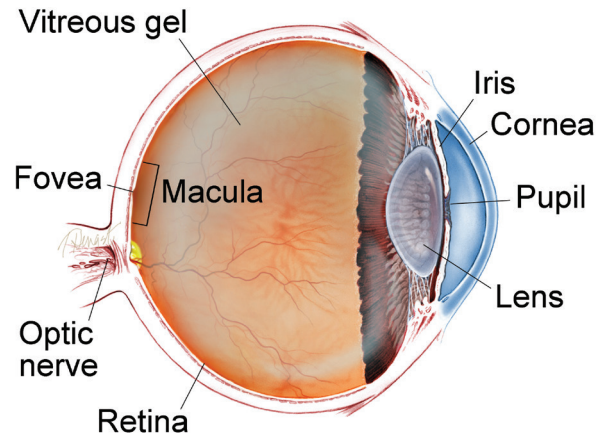
**Diagnostic Testing:** Viewing the retina with an **indirect ophthalmoscope** while the doctor applies gentle pressure to the eye (scleral depression) is the primary method for diagnosing retinal detachment. When view of the retina is obscured (blocked) by blood or dense cataract, **B-scan ultrasonography** can be used to determine the location and extent of a retinal detachment (*Figure 2*). To confirm whether there is subretinal fluid in the macula, **optical coherence tomography** (OCT) may be used.

**Treatment and Prognosis:** The only treatment option for complex retinal detachment is retinal surgery. Patients may undergo **pars plana vitrectomy** with peeling of membranes, a **scleral buckling** procedure, or both. Use of special retinal detachment repair strategies, including **retinectomy** or **perfluorocarbon liquid**, may be necessary in patients with complex retinal detachments.

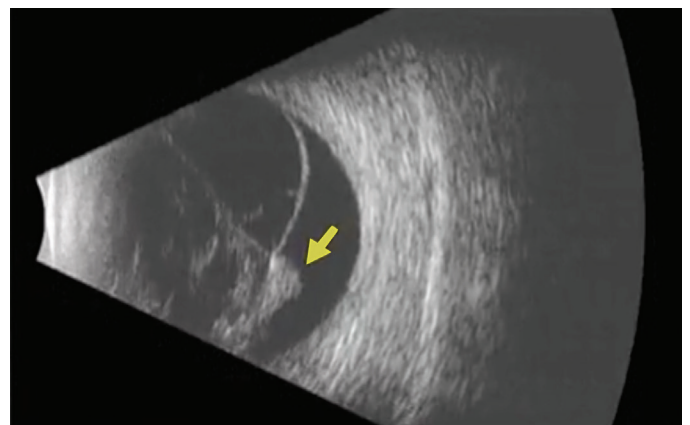
Laser is also used in combination with the vitrectomy to seal the retinal breaks. Your surgeon will decide which procedure is best depending

*continued next page*

### WHAT IS THE RETINA?



**THE RETINA** is a thin layer of light-sensitive nerve tissue that lines the back of the eye (or vitreous) cavity. When light enters the eye, it passes through the iris to the retina where images are focused and converted to electrical impulses that are carried by the optic nerve to the brain resulting in sight.



**Figure 2**

B-scan ultrasound of a patient with PVR-related retinal detachment. A fixed retinal fold (yellow arrow) is seen with a cone-shaped retinal detachment. (Photo courtesy of Yale Fisher, MD. Retina Image Bank, © American Society of Retina Specialists.)

## Complex Retinal Detachment: Proliferative Vitreoretinopathy and Giant Retinal Tears *continued from previous page*

on the nature of your detachment. At the end of surgery, most patients with complex retinal detachment due to PVR or a giant retinal tear will receive a long-acting gas bubble or silicone oil filling into the vitreous cavity of the eye to hold the retina in position while the eye heals.

Research is being conducted to find a medical therapy to prevent and treat PVR, but to date, none has proven effective in most patients. ●

### SYMPTOMS

**Many patients with PVR report symptoms of retinal traction (pulling), such as floaters or flashes of light. Accumulation of fluid underneath the retina results in a loss of peripheral (side) vision.**

When the detachment involves the center of the retina, called the **macula**, central vision loss will occur. Patients with chronic retinal detachment may also develop problems such as elevated pressure in the eye and inflammation.

Some patients experience no symptoms, particularly:

- Younger patients
- Cases where the macula is not involved
- Patients whose detachment has progressed slowly

But, most often, patients will have some visual symptoms.

### RISK FACTORS

**Many risk factors for PVR have been identified, including:**

- Large or multiple retinal tears
- Giant retinal tears
- Vitreous hemorrhage—a leakage of blood into the gel that fills the eye cavity
- Choroidal detachment—separation of the choroid from the sclera (the white of the eye)
- Eye trauma (injury)
- Multiple previous surgical procedures ●

*continued next page*

## Complex Retinal Detachment: Proliferative Vitreoretinopathy and Giant Retinal Tears *continued from previous page*

### Clinical Terms (*appearing green within fact sheet text*)

**B-scan ultrasound:** Sound waves are used to form an image of the back of the eye during ocular movements. This allows identification of spatial relationships of structures within the eye.

**Choroid** (pronounced *CORE oid*): The layer of blood vessels and connective tissue between the retina and the white of the eye, also known as the *sclera*.

**Floater:** Mobile blurry shadow that partially obscures vision. Floaters are most bothersome when near the center of vision and less annoying when they settle to the side of the vision. They may appear like cobwebs, dust, or a swarm of insects—or in the shape of a circle or oval, called a *Weiss ring*.

**Indirect ophthalmoscope:** Medical instrument used to examine the interior of the eye. This looks a bit like a miner's helmet.

**Macula:** A small area at the center of the retina where light is sharply focused to produce the detailed color vision needed for tasks such as reading and driving.

**Optical coherence tomography (OCT):** A non-invasive imaging technique that uses light to create a 3-dimensional image of your eye for physician evaluation.

**Perfluorocarbon liquid:** A heavier than water clear liquid that can be injected into the eye to help push the retina back against the eye wall. It is typically placed temporarily into the vitreous during vitrectomy to hold the retina while the retinal surgeon repairs the retina.

**Retinectomy:** Surgical removal of a portion of retinal tissue. This is sometimes required where there is severe scar tissue contracting the retina that cannot be peeled from the surface of the retina.

**Scleral buckle:** A piece of silicone rubber or sponge sutured to the outer wall of the eye posterior to the rectus eye muscles. The scleral buckle helps to indent the eye to support the peripheral retina and pushes the outer eye against the retina in eyes with a retinal detachment.

*continued next page*

## Complex Retinal Detachment: Proliferative Vitreoretinopathy and Giant Retinal Tears *continued from previous page*

### Clinical Terms

*(appearing green within fact sheet text)*

**Vitrectomy surgery (also called pars plana vitrectomy surgery):** A procedure undertaken by a specialist where the vitreous gel that fills the eye cavity is removed to provide better access to the retina. This allows for a variety of repairs, including the removal of scar tissue, laser repair of retinal detachments and treatment of macular holes. Once surgery is complete, a gas bubble or silicone oil may be injected into the vitreous gel to help hold the retina in position.

### THANK YOU TO THE RETINA HEALTH SERIES AUTHORS

Sophie J. Bakri, MD  
Audina Berrocal, MD  
Antonio Capone, Jr., MD  
Netan Choudhry, MD, FRCS-C  
Thomas Ciulla, MD, MBA  
Pravin U. Dugel, MD  
Geoffrey G. Emerson, MD, PhD  
Roger A. Goldberg, MD, MBA  
Darin R. Goldman, MD  
Dilraj Grewal, MD  
Larry Halperin, MD  
Vincent S. Hau, MD, PhD  
Suber S. Huang, MD, MBA  
Mark S. Humayun, MD, PhD  
Peter K. Kaiser, MD  
M. Ali Khan, MD  
Anat Loewenstein, MD  
Mathew J. MacCumber, MD, PhD  
Maya Maloney, MD  
Hossein Nazari, MD  
Oded Ohana, MD, MBA  
George Parlitsis, MD  
Jonathan L. Prenner, MD  
Gilad Rabina, MD  
Carl D. Regillo, MD, FACS  
Andrew P. Schachat, MD  
Michael Seider, MD  
Eduardo Uchiyama, MD  
Allen Z. Verne, MD  
Yoshihiro Yonekawa, MD

### EDITOR

John T. Thompson, MD

### MEDICAL ILLUSTRATOR

Tim Hengst